

OPTIMAL OF b-VALUE IN DIFFUSION WEIGHTED MRI FOR BENIGN AND MALIGNANT BREAST LESIONS

Muhammad Fiaz,¹ Zaheer Mustafa,² Amara Saeed Malik,¹ Nasir Mahmood,³ Saeed Akhtar Malik²

ABSTRACT

Background: Diffusion weighted imaging explores the random motion of water molecules in the body and the diffusion sensitivity is varied by parameter known as the “b value”. DWI sequence derives quantitative and qualitative data reflecting changes at cellular level and information on the tumor cellularity.

Objective: To find out the optimal b-value for lesion detection and calculation of ADC value to differentiate between benign and malignant breast lesions.

Methodology: This was a cross sectional study. Bilateral MRI breast scans were conducted in 60 patients 20 benign, 20 malignant and 20 females with normal breasts at 1.5T with DWI sequence b-value of 300, 600 and 1000 and the ADC values were calculated. Optimal b-value for depiction of lesion was calculated and lesions were characterized as benign or malignant upon b-value of DWI and ADC values of the lesions.

Results: The optimal b-value for lesion conspicuity was found to be 600 but the b-value for lesion characterization through ADC value was 1000. ADC values were acquired for each b-value combination. ADC values were found higher for benign breast lesions than malignant lesions at b value of 600, ADC value was 1.54 ± 0.15 for benign lesions, 0.85 ± 0.19 for malignant lesions and 2.25 ± 0.25 for normal breast.

Conclusion: DWI sequences has a promising application in diagnosing of breast lesions. Normalized ADC values assists differential diagnosis.

Key words: MRI, DWI sequence, ADC, Breast lesions.

INTRODUCTION

Diffusion-weighted imaging (DWI) relies on the detection of the random microscopic motion of free water molecules known as Brownian movement.¹ Restriction in the diffusion of water molecules is directly proportional to the degree of cellularity of the tissue.^{1,2}

DWI: It incorporate two symmetric motion-probing gradient pulses into a single-shot spin-echo (SE) T2-weighted gradient sequence, one on either side of the 180° refocusing pulse (Stejskal-Tanner sequence)³ “b-value” is an index of the degree of diffusion weighting.

Qualitative Analysis: Visual assessment of relative attenuation of signal intensity.⁴

Quantitative Analysis: Calculation of Apparent Diffusion Coefficient (ADC) value of the ROI.⁵

Limited studies suggesting the single optimal b values and ADC values for the Pakistani population. Aid in detecting breast cancer at an early stage and in dense breast since Ultrasound/Mammography can provide false negative diagnoses in young women.^{6,7}

Characterization of tumor quantitatively, hence it is an alternative for invasive procedures. Estimating single optimal b-value can save examination time.⁸ DWI sequences resolve detection and characterization of breast tumor for

patients contraindicated for gadolinium based contrast enhanced study. It gives positive predictive value for tumor response in neo adjuvant therapy and screening sequence for high risk population.⁹ The study was conducted to find out the optimal b-value for breast lesions detection by visual assessment and to find out the optimal b-value for calculation of ADC value for normal breast tissue and to differentiate benign and malignant breast lesions.

METHODOLOGY

This was cross sectional study, conducted at SEIMENS MRI 1.5T, 16 channel system at Department of Radiology, Alrazi Hospital, Lahore and Sheikh Zayed Hospital Rahim Yar Khan. This study included 20 female having benign breast lesions, 20 having malignant lesions and 20 female with normal breasts. Convenience sampling technique was used.

Inclusion criteria: Female with age group from 25-55 years. Breast lesion as reported by ultrasonography or mammography. MRI scheduled 7th-15th day of the menstrual cycle.

Exclusion criteria: Subjects with silicon/metallic implants, post surgery/biopsy/ chemotherapy and cystic lesion:

MRI pulse sequences taken were;

1. Al-Razi Health Care, Lahore, Pakistan.

2. Department of Radiology & Diagnostic Imaging, Sheikh Zayed Medical College/Hospital, Rahim Yar Khan, UHS, Lahore, Pakistan.

3. Pak Red Crescent Medical & Dental College, Kasur, Pakistan.

Correspondence: Dr. Zaheer Mustafa, Associate Professor, Sh. Zayed Medical College/Hospital, Rahim Yar Khan, Pakistan.

Email: zaheermustafa1@gmail.com

Phone: +92-3009670650

Received: 21-10-2018

Accepted: 03-11-2018

Published: 29-03-2019

1. T2 (Fat Suppression) sequences for localization of the breast lesion.
2. DWI sequences with three sets of b-value (0-300, 0-600, 0-1000).

ADC value Calculation (Quantitative Analysis):
Post processing of the DWI acquired images was done in Syngo Extended Workstation-Fiber tracking software application, to obtain ADC parametric maps of the region of interest. For a lesion measuring of 1- 2 cm = 3 ROIs, 2.1cm and above = 6 ROIs were considered, which was individually placed in the tissue and the average ADC was then acquired for each b-value combination. A histopathological report were obtained for all lesions for diagnosis were followed up for 2 years. The obtained data were statistically analyzed in SPSS 16 version. Ethical approval was sought from Institutional Review Board.

Visual Assessment (Qualitative Analysis):
Radiologists of 5 years of experiences independently (blinded) evaluated DWI images. Criteria for image evaluation were:

1. Subjective Signal to Noise Ratio (SNR)
2. Lesion vs glandular differentiation
3. Glandular vs fatty differentiation
5. Point Likert scale

Depending upon above observations, following grading was done, and only excellent images were included in study.

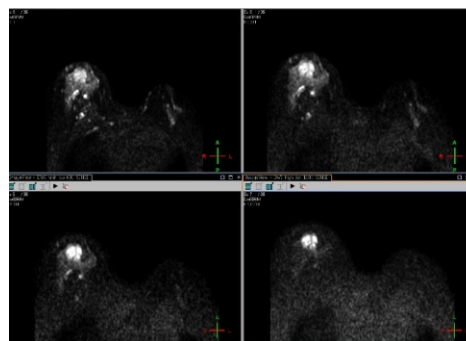
- 1 = Bad
- 2 = Inferior
- 3 = Average
- 4 = Good
- 5 = Excellent

RESULTS

This study accessed ADC values at b value of 300, 600 and 1000, for breast lesions. In this study total, 60 females were assessed, 20 having benign breast legions, 20 having malignant lesion and 20 females with normal breasts. After performing MRI breast scans, DWI were analyzed for b-value of 300, 600 and 1000 and their ADC values were calculated.

Figure I: DWI sequences of malignant lesion on the right breast

- a. b=0
- b. b=300
- c. b=600
- d. b=1000



Optimal b-value for quantitative analysis for lesion depiction was found to be of b-value 600 and b – value for lesion characterization through ADC was 1000. Results showed that ADC values were higher for benign lesions than malignant breast lesion. Quantitative analysis of DW images for lesion detection and ADC values of different tissues are summarized in following table I.

Table I: Type of tissues and their ADC values by using 3 sets of b-values

b-value	Types of tissues (ADC 10^{-3} sec/mm ²)		
	Benign	Malignant	Normal
0,300	1.6±0.24	0.84±0.17	2.07±23
0,600	1.57±0.10	0.90±0.15	2.11±0.25
0,1000	1.54±0.15	0.85±0.19	2.25±0.25

*Note: Data are the mean ± standrad deviation

Cut off value- 1.33×10^{-3} mm²/sec

Optimal b-value for qualitative analysis for lesion detection , b- value = 600

DISCUSSION

Breast lesions are gradually increasing in female population of Pakistan. Ultrasonography, mammography and FNAC are common methods for detection for breast lesions.¹⁰ MRI is now frequently used for detection of breast tumors by using dedicated breast coils. DW images with various b-values and than calculation of ADC values are latest methods for early detection of benign or malignant lesions.¹¹ In our study, it was found that ADC values were higher in benign breast lesions than malignant

Table II: Comparison of studies

Study/Year	No. of Lesions	b- Value (sec/mm ²)	Types of tissues (10-3 mm ² /sec)			Cut off value 10-3 mm ² /sec
			Benign	Malignant	Normal	
Yong Guo ¹ 2002,China	Benign-24, Malignant-31	0, 250, 500, 750, 1000	1.57±0.23	0.97±0.20	-	1.30
Erika Rubesova ² 2006,Belgium	Benign-22 Malignant-65	0, 200,400, 600, 1000	1.51±0.068	0.95±0.027		1.13
C. Marini ⁵ 2007,Italy	Benign-21 Malignant-42	0,1000	1.48±0.37	0.95±0.18	-	1.31
W. Bogner ⁶ 2009,Austria	Benign-17 Malignant- 24, Normal- 51	0, 50, 100, 250, 400, 550, 700,850, 1000,1250	1.47±0.21	0.99±0.18	1.85±0.22	1.25
Qinghua Min ³ 2015,China	Benign-20 Malignant-29	0,400,600, 800	1.66 ± 0.90	1.11 ± 0.37	-	1.23
Tuğba Bostan ⁴ 2016,Turkey	Benign-23 Malignant- 35, Normal- 46	0,750	1.61±0.50	1.04±0.29	1.92±0.52	1.30
Present study	Benign-20 Malignant- 20, Normal- 20	0,300,600,1 000	1.54±0.15	0.85±0.19	2.25±0.25	1.33

lesions. Results are comparable with various studies conducted in different countries and summarized in table II.

CONCLUSION

DWI plays a significant role in breast imaging. ADC is an effective parameter in distinguishing between benign and malignant breast lesions. ADC varied substantially with the choice of different b-values, indicating that absolute ADC threshold values should be interpreted with cautions. Diffusion Weighted MR technique helps in improving the positive predictive value for detection and characterization of breast lesions. DWI should be implemented to routine breast MRI protocol.

Authors Contribution: ZM: Data Collection,

Idea generation and Literature Review. MF & ASM: Data Analysis and Interpretation. NM & SAM: Worked on discussion Section. All authors critically revised and approved its final version.

Conflict of Interest: None

Sources of Funding: None

REFERENCES

1. Guo, Y., Cai, Y.-Q., Cai, Z.-L., Gao, Y.-G., An, N.-Y., Ma., Differentiation of clinically benign and malignant breast lesions using diffusion-weighted imaging. *Journal of Magnetic Resonance Imaging*, 2002; 16(2):172–178.
2. Rubesova, E., Grell, A.-S., De Maertelaer, V., Metens, T., Chao, S.-L., & Lemort, M.. Quantitative diffusion imaging in breast cancer: a clinical prospective study. *Journal of Magnetic Resonance Imaging: JMIR*, 2006; 24(2), 319–324.
3. Min, Q., Shao, K., Zhai, L., Liu, W., Zhu, C., Yuan, L., & Yang, J. Differential diagnosis of benign and malignant breast masses using diffusion-weighted magnetic resonance imaging. *World Journal of Surgical Oncology*,

- 2015;13(1).
4. Tuğba Bostan Bozkurt, Gonca Koç, Gülten Sezgin, Canan Altay, M. Fazıl Gelal, Orhan. Value of Apparent Diffusion Coefficient Values in Differentiating Malignant and Benign Breast Lesions. *Trakya University Faculty of Medicine, Balkan Medical Journal* 2016;33:294-300.
 5. Marini C, Iaconi C, Giannelli M, Cilotti A, Moretti M, Bartolozzi C. Quantitative diffusion-weighted MR imaging in the differential diagnosis of breast lesion. *Eur Radiol.* 2007;17:2646–55
 6. Bogner W, Gruber S, Pinker K, Grabner G, Stadlbauer A, Weber M, Moser E, Helbich TH, Trattng S. Diffusion-weighted MR for differentiation of breast lesions at 3.0 T: how does selection of diffusion protocols affect diagnosis? *Radiology.* 2009; 253(2):341–51.
 7. Chen, X., He, X.-J., Jin, R., Guo, Y.-M., Zhao, X., Kang, H.-F Wu, Q.. Conspicuity of breast lesions at different b values on diffusion-weighted imaging. *BMC Cancer*, 2012;12(1): 334-9.
 8. Sinha S, Lucas-Quesada FA, Sinha U, DeBruhl N, Bassett LW. In vivo diffusion-weighted MRI of the breast: potential for lesion characterization. *Journal of Magnetic Resonances Imaging* 2002; 15:693–704
 9. Wenkel E, Geppert C, Schulz-Wendtland R, et al. Diffusion weighted imaging in breast MRI: comparison of two different pulse sequences. *Acad Radiol* 2007; 14:1077–1083
 10. Jones DK, Horsfield MA, Simmons A. Optimal strategies for measuring diffusion in anisotropic systems by magnetic resonance imaging. *Magn Reson Med* 1999; 42:515–525.
 11. Tamura, T., Usui, S., Murakami, S., Arihiro, K., Fujimoto, T., Yamada T, Akiyama, M.. Comparisons of multi b-value DWI signal analysis with pathological specimen of breast cancer. *Magnetic Resonance in Medicine*, 2012; 68(3): 890–897.

Article Citation: Fiaz M, Mustafa Z, Malik AS, Mahmood N, Malik SA. Optimal of B-value in diffusion weighted MRI for benign and malignant breast lesions. *JSZMC* 2019;10(1):1549-52